

Pediatric Urologic Emergencies and Urgencies

Jeffrey A. Leslie, MD, Mark P. Cain, MD*

*Division of Pediatric Urology, Indiana University School of Medicine,
J.W. Riley Hospital for Children, 702 Barnhill Drive, #4230, Indianapolis, IN 46202, USA*

This article focuses on problems that might be encountered by primary care physicians in the hospital or clinic setting that require emergent or urgent pediatric urological referral. Although it is not an exhaustive review, the more common urologic problems seen in infancy and childhood are covered, with a brief description of the usual presenting signs or symptoms, differential diagnoses, proper diagnostic work-up recommended before or at the time of referral, and the usual therapeutic course of management after evaluation by the urologist.

The acute scrotum

One of the most common urgent urologic problems seen by primary care physicians is the child who has abnormal scrotal swelling, usually associated with pain or erythema. On the forefront of each clinician's mind is the possibility of testicular torsion. The diagnosis of testicular torsion, however, is not always straightforward because other processes such as torsion of a testicular or epididymal appendage, epididymitis, tumor, incarcerated hernia, trauma, insect bite, or even Henoch-Schönlein purpura can lead to a similar clinical presentation. The history and physical examination, timing of presentation relative to the onset of the symptoms, and the age of the child are often the key to making an expedient diagnosis and referral. The only condition that requires emergent surgery is testicular torsion, which is associated with a history of pain for less

* Corresponding author.

E-mail address: mpcain@iupui.edu (M.P. Cain).

than 48 hours. Beyond this time frame, testicular salvage is uniformly poor and, thus, emergent exploration is not usually indicated.

Testicular torsion presents in a bimodal age presentation, with extravaginal torsion occurring in the perinatal period and intravaginal torsion peaking in puberty, although the latter can be seen at any age. The management of extravaginal torsion (Fig. 1), which occurs during testicular descent, is controversial, and the complexities of this issue are beyond the scope of this article. Some urologists advocate no surgical intervention, whereas others recommend surgical exploration, with excision of the necrotic testis and contralateral fixation because metachronous contralateral torsion has been seen and results in lifelong serious implications with respect to fertility and hormone production. Most urologists agree that an infant born with unilateral torsion can be stabilized and explored on a semielective basis to optimize anesthetic risk; however, infants who have normal testes documented at birth who subsequently are noted to have an acute scrotum require emergent exploration. Other etiologies to consider in the differential diagnosis of a swollen, indurated neonatal scrotum include lesions resulting from a patent processus vaginalis, including trapped meconium and hemoscrotum from intra-abdominal hemorrhage.

Intravaginal torsion is believed to be due to an abnormal fixation of the testis within the tunica vaginalis, allowing the testis to twist, especially during periods of testicular growth such as puberty (Fig. 2). Patients usually present with acute onset of pain, perhaps associated with minor trauma, followed by nausea, vomiting, and exquisite tenderness to palpation. With time, the affected hemiscrotum becomes erythematous and edematous, and a reactive hydrocele may form that can make examination of the testicle more difficult. When examined early in the course of torsion, the testis is often noted to have a transverse lie and may be higher riding than the contralateral testis. This presentation is classic for testicular torsion, and no further evaluation or imaging is needed before emergent surgery.

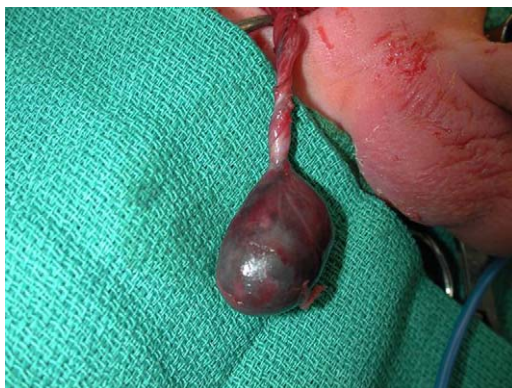


Fig. 1. Extravaginal (neonatal) testicular torsion.

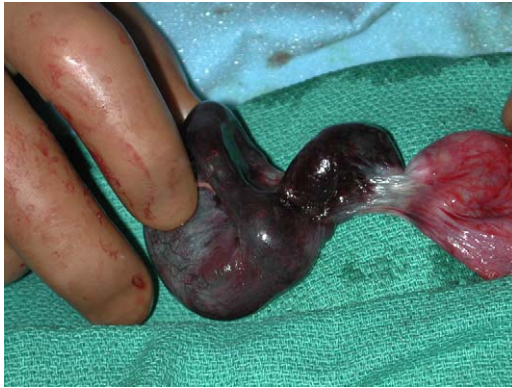

Fig. 2. Intravaginal testicular torsion.

A cremasteric reflex, elicited by gently stroking the ipsilateral inner thigh with subsequent testicular ascent, is classically absent in cases of torsion. Occasionally, one is able to elicit a history consistent with prior similar episodes of pain that resolved spontaneously, consistent with torsion and spontaneous “detorsion.” This condition is commonly referred to as intermittent torsion and is associated with subsequent testicular torsion. With acute torsion, testicular salvage is directly related to duration of symptoms before exploration, with excellent salvage expected with less than 6 hours of symptoms but progressively worse rates thereafter. Beyond 48 hours, the salvage rate is uniformly poor; thus, expedient exploration under optimal anesthetic conditions is usually favored. It is unfortunate that many patients delay presentation and the diagnosis becomes more obscure. In these situations, urinalysis, white blood count, and Doppler ultrasonography or a nuclear testicular blood flow scan may be indicated, if available.

Torsion of an epididymal or testicular appendage (Fig. 3) presents in a manner similar to testicular torsion, although classically, it is not associated with systemic symptoms such as nausea and vomiting or pain as severe as that seen with testicular torsion. When performing an examination early in the onset of symptoms, the clinician can often localize the point of tenderness to the upper pole of the testis or epididymis or observe a blue spot through the scrotal skin—the so-called “blue dot sign” [1]. Torsion of an appendage is usually a self-limited process, which can be managed with reassurance, bed-rest, and analgesics, with the expectation that symptoms will resolve in 3 to 5 days. If protracted pain occurs, then exploration with excision of the appendage can be performed on an outpatient basis, with immediate resolution of the symptoms.

History of dysuria, recent fever or mumps, and new incontinence or dysfunctional voiding along with pyuria or bacteriuria is highly suggestive of epididymitis or orchitis, which can be seen in pre- and postpubertal boys. History of recent urethral instrumentation, catheterization, or sexual activity should also

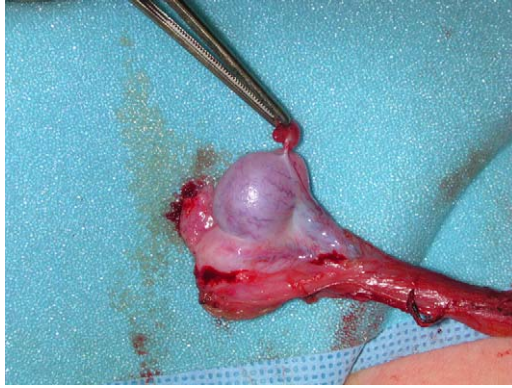


Fig. 3. Torsion of appendix testis.

be obtained. Often, one is able to elicit a history of recent sudden increases in abdominal pressure such as straining, lifting, or trauma, leading to reflux of sterile urine down the ejaculatory duct and vas deferens that can initiate epididymal inflammation. Doppler ultrasound reveals good perfusion of the testicle, often with enlargement and increased blood flow to the epididymis or testicle compared with the contralateral unit. Boys who have epididymitis and positive urine cultures not associated with instrumentation or sexual activity require diagnostic evaluation with renal-bladder ultrasound and voiding cystourethrography (VCUG) after the inflammation has resolved.

It should be mentioned while discussing the evaluation of the acute scrotum with Doppler ultrasound that not all boys who have an acute scrotum require an ultrasound. A clear history and physical examination consistent with testicular torsion is an immediate indication for surgery, without delaying to perform any further studies. Ultrasound is most useful in the setting of a difficult examination, a delay in presentation, or an equivocal history. Doppler ultrasonography is technician dependent and not 100% sensitive or specific for diagnosing testicular torsion; however, when used in equivocal cases and incorporated into the history, examination, and other clinical data, it can be a very helpful tool [2,3].

Scrotal trauma is a relatively common presentation in active boys, usually due to a direct blow or straddle injury. As mentioned previously, such a blow can lead to torsion, although it more commonly results in a scrotal hematoma or ecchymosis that can be impressive on examination due to the laxity of the scrotum. The examination can be difficult if a hematoma has already developed at the time of presentation, in which case Doppler ultrasound can be a useful adjunct. As with torsion, however, the ultrasound must be correlated with the history and examination findings. Testicular rupture can be present despite an ultrasound that appears to demonstrate an intact tunica albuginea. If the testicle cannot be clearly demonstrated on examination to be intact, urgent referral to a urologist is indicated because rupture of the testicle requires surgical repair.

Other scrotal abnormalities

Intrascrotal tumors are uncommon in children. They usually present with nontender enlargement of the scrotum. The differential diagnosis includes primary testicular tumors (benign and malignant) and paratesticular tumors such as rhabdomyosarcoma. Prompt evaluation by a urologist is necessary, including serum β -human chorionic gonadotropin and alpha fetoprotein levels for suspected intratesticular tumors. Scrotal ultrasound frequently helps confirm the location of the mass and is sometimes helpful in differentiating benign from malignant tumors.

Incarcerated inguinal hernia can present as a tender or nontender scrotal swelling that is differentiated from the previously mentioned entities by the persistent mass and induration extending to the inguinal area on examination. These children may have a prior history suggestive of a patent processus vaginalis, such as intermittent ipsilateral scrotal swelling. They may or may not transilluminate because bowel in such hernias is often edematous. Manual reduction can usually be performed with sedation, allowing delayed surgical exploration under optimal anesthetic conditions. Testicular injury can occur from torsion due to the effect of the incarcerated hernia or due to ischemia from cord compression, thus further mandating emergent reduction of the hernia or surgical exploration if reduction is not possible.

Noncommunicating hydroceles and spermatoceles or epididymal cysts (after puberty) can also present with nontender scrotal swelling and usually transilluminate. They can be differentiated from hernias by the lack of persistent mass in the upper scrotum and external inguinal ring along the spermatic cord. Noncommunicating hydroceles can be electively corrected after the age of 2 years if desired. Spermatoceles do not require excision unless desired by the patient or family.

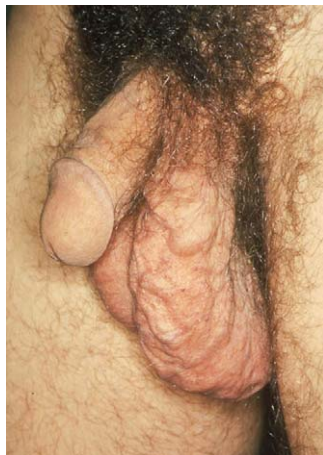

Fig. 4. Large left varicocele.

Varicoceles, which are present in 15% of boys, can also present to the primary care physician around the onset of or after puberty as a scrotal swelling that is of concern to the boy or due to persistent discomfort (Fig. 4). Examination of the cord structures with the patient standing and then supine or with and without Valsalva maneuver can usually demonstrate enlargement of the veins along the cord structures. Routine referral to a urologist is recommended to discuss the management of varicoceles, which is somewhat controversial and complicated in many cases. An acute varicocele in a prepubertal boy requires urgent evaluation because it may be the first sign of a retroperitoneal process (eg, Wilms' tumor).

Penile abnormalities

Boys who have a swollen, erythematous penis often present to the emergency department or primary care clinic. The common differential diagnosis of these boys includes paraphimosis, balanitis, posthitis, balanoposthitis, hair tourniquet, and insect bite.

Paraphimosis occurs only in uncircumcised boys and is a surgical emergency because ischemic injury to the glans can occur if not remedied promptly. This condition occurs when a phimotic ring of foreskin is retracted, often by the child or by the parent who is cleaning the penis, becoming trapped proximal to the coronal sulcus, which results in significant edema of the glans penis. Treatment involves reduction of the foreskin, which can often be performed manually after applying gentle constant pressure to the edematous foreskin with or without local anesthesia (penile block) or surgically by division of the phimotic ring. Circumcision is advisable in these boys at some point after the occurrence.

Balanitis (inflammation of the glans penis), posthitis (inflammation of the foreskin), and balanoposthitis (inflammation of the glans and the foreskin) are frequent conditions seen in the emergency department or clinic. In most cases, the etiology is nonspecific, usually caused by inadequate hygiene of the inner prepuceal sulcus or by external irritation (contact dermatitis) from soaps, bubble bath, laundry detergents, or persistent manual manipulation (foreskin fiddling). Colonization by *Candida albicans* or anaerobic gram-positive bacteria may be present, associated with inability to retract the foreskin and accumulation of smegma. In these cases, a discharge is usually absent, and treatment involves gentle cleaning of the foreskin sulcus, sitz baths, and application of 0.5% hydrocortisone cream. In more severe cases, when the foreskin cannot be easily or comfortably retracted, saline solution or water may be injected under the foreskin with a small angiocatheter. If these measures are not effective or if the inflammation recurs, then a short course of oral antibiotics may be required to eliminate the organisms that may produce irritating enzymes. Persistent phimosis can be treated with a 0.05% to 0.1% betamethasone cream for 2 to 6 weeks, which is frequently successful in allowing retraction of the foreskin and improved

hygiene. If a purulent discharge, intense fiery-red erythema, and a moist transudate or exudate is present, then a streptococcal etiology should be considered. A rapid antigen test or culture of the discharge should be ordered, and treatment with a 10-day course of an antistreptococcal antibiotic initiated [4]. If a true urethral discharge is present, which can at times be elicited by milking the length of the urethra proximally to distally, then sexually transmitted diseases such as gonorrhea or chlamydia should be entertained and gram stain, cultures, and DNA probes obtained. If either organism is confirmed, then treatment for both gonorrhea and chlamydia should be given (ceftriaxone, 125 mg, intramuscularly and azithromycin, 1 g, orally).

Hair tourniquet is a surgical emergency similar to paraphimosis in appearance and pathophysiology. Ischemic injury to the glans may occur if not relieved promptly by division and removal of the hair strand.

Circumcision injuries are rare but occasionally occur and often require urgent referral to a pediatric urologist. If amputation of the glans or shaft occurs, the penis should be wrapped in moist gauze and the amputated tissue placed in a sterile, saline-soaked gauze wrap on ice for transport to the urologist. The more common injury involves partial degloving of the penile shaft skin due to excessive skin removal, which can be managed with topical antibiotic ointment with delayed secondary healing.

Exstrophy

Exstrophy is a rare condition that is now frequently diagnosed antenatally, allowing for delivery in a tertiary center where pediatric urologists are available for immediate care of these infants. When unexpected delivery of a child who has exstrophy occurs, however, the child should immediately be transferred to a tertiary center where a pediatric urologist with expertise in the care of these infants is available. The care of the infant before transfer should include suture ligation of the umbilical cord, rather than clamping, to avoid erosion of the exstrophy plate. In addition, a nonadherent protective dressing such as nonsterile cellophane should be applied rather than gauze, which can denude the mucosa when removed. A renal ultrasound is necessary soon after birth but should not delay transport of the neonate. If cloacal exstrophy is present, gender assignment may be difficult and should therefore be deferred to the referral center. In both cases, broad-spectrum antibiotic prophylaxis should be initiated at birth.

Hematuria

Hematuria in children is associated more frequently with medical problems than with surgical problems. Gross or microscopic hematuria in the setting of

blunt trauma in a child mandates imaging with contrast-enhanced CT scan [5], with urologic consultation if urinary tract injury is identified on the scan. Blood at the meatus associated with trauma, especially with pelvic fractures, requires a retrograde urethrogram before any attempts to place a urethral catheter.

Outside the setting of trauma, gross hematuria can result from interstitial, glomerular, vascular, or urinary tract/urothelial sources such as acute urinary tract infection (UTI) or tumors. Most of these cases do not require urgent urologic consultation unless the hematuria is so severe as to result in clots or urinary retention, which is unusual in children. If the child is asymptomatic and proteinuria, hypertension, edema, or renal insufficiency is associated with the hematuria, then medical etiologies should be investigated. When symptoms of a UTI are present (dysuria, frequency, fever, urgency) urinalysis and culture (with appropriate antibiotic treatment) is required, with elective work-up of the urinary tract with ultrasound and VCUG after resolution of the infection. When renal colic is present, a noncontrast CT scan of the abdomen and pelvis with thin slices (helical scan) should be obtained to rule out a urinary tract stone. In children who have none of these signs or symptoms, a urine culture, spot urinary calcium/creatinine ratio (to exclude hypercalciuria), or 24-hour urine for calcium and renal ultrasound should be considered in addition to hemoglobin electrophoresis in black children (sickle cell trait or disease) and testing of the parents for hematuria (benign familial hematuria). If hypercalciuria, nephrocalcinosis, a urinary tract tumor, hydronephrosis, or UTI is discovered with this evaluation, then elective referral to a pediatric urologist is warranted.

Urinary retention and bladder outlet obstruction

Urinary retention is a frequent presentation in adults but relatively infrequent in children. There is little in the literature regarding this entity in pediatrics. An excellent retrospective review of retention in children was recently published by Gatti and colleagues [6] and is recommended as a more exhaustive resource. These investigators identified 53 children who presented with urinary retention (inability to void for >12 hours, palpably distended bladder, greater than expected volume in bladder) not associated with previously known neurologic processes, voiding dysfunction, immobility, or recent surgery. The most common etiologies for retention identified in these children were neurologic processes (17%), severe voiding dysfunction (15%), UTI (13%), constipation (13%), adverse drug effect (13%), local inflammatory causes (7%), locally invading neoplasms (6%), benign obstructing lesions (6%), and idiopathic etiologies (6%). One child presented with UTI and constipation and one child presented with an incarcerated inguinal hernia. This review points out the wide spectrum of diseases that can affect bladder function. Thorough neurologic examination, physical examination including a rectal examination (local obstructing masses/tumors) and careful inspection of the lumbar spine area, urinalysis and culture, and bowel function

history are crucial to determining the etiology and treatment beyond temporary catheterization. Urologic referral in such cases is usually indicated. Bladder outlet obstruction can occur from a variety of lesions, some of which are covered in the genital abnormalities section; specifically, those occurring in girls. Bladder outlet obstruction in boys may present with frank retention, palpably distended bladder, renal failure, hydronephrosis (unilateral or bilateral), UTI, hematuria, or dysfunctional voiding. Etiologies include posterior urethral valves, anterior urethral valves, congenital urethral stricture, or a large ureterocele that prolapses into the urethra or bladder neck.

Posterior urethral valves are now often discovered on prenatal ultrasound and show a distended, thick-walled bladder without normal cycling, bilateral or unilateral hydronephrosis, oligohydramnios, and renal dysplasia. After birth, initial management should include serum electrolytes and creatinine measurement, placement of a urethral catheter, and a renal-bladder ultrasound. Immediate urologic consultation should be obtained because the management of children who have posterior urethral valves is complex. The catheter should be carefully placed by someone experienced in urethral catheterization because it may coil in a dilated proximal urethra. When catheter drainage has been established, serial creatinine measurements and electrolytes should be monitored until the nadir creatinine is identified. These children should also be placed on prophylactic antibiotics until the work-up can be completed. Further management depends on the child's overall condition, renal function, and surgeon's preference of primary endoscopic valve ablation or urinary diversion by vesicostomy (less common).

Genital abnormalities

Genital abnormalities that may require urgent urologic evaluation include ambiguous genitalia, hypospadias with a nonpalpable testis, and interlabial masses. The newborn who has ambiguous genitalia often presents a social emergency for the involved family and a potential medical emergency, owing to the potential presence of a life-threatening, salt-wasting form of congenital adrenal hyperplasia. The evaluation and management of ambiguous genitalia is complex and beyond the scope of this review; however, some general recommendations are provided.

The newborn who has ambiguous genitalia requires an evaluation of karyotype, serum electrolytes, 17-OH progesterone, testosterone, luteinizing hormone, and follicle stimulating hormone levels in the immediate perinatal period. Possible presentations include clitoral enlargement with a palpable labioscrotal mass, microphallus with hypospadias, and clitoromegaly with labial fusion. If the 17-OH progesterone level is elevated, then congenital adrenal hyperplasia exists. If the 17-OH progesterone level is normal, then further endocrine evaluation of the androgen hormone axis is required with determination of the testosterone/

dihydrotestosterone ratio, along with testosterone, luteinizing hormone, and follicle stimulating hormone levels before and after human chorionic gonadotropin stimulation.

In addition, the male infant who has bilateral or a unilateral impalpable testis should be regarded as having an intersex condition until proven otherwise. In such cases, a thorough prenatal history should be obtained, including ingestion of exogenous maternal hormones (such as used with assisted reproductive techniques) or maternal use of contraceptive hormones during pregnancy. Family history of urologic abnormalities, unexplained neonatal deaths, precocious puberty, amenorrhea, infertility, or consanguinity should also be elicited.

Interlabial masses include Gartner's duct cyst, imperforate hymen with hydrocolpos or hydrometrocolpos, prolapsed urethra or ureterocele, and tumors such as sarcoma botryoides. Although these conditions usually do not require emergent surgical intervention, they frequently require urgent evaluation by a urologist.

The examination of a female infant who has a Gartner's duct cyst reveals a normal urethral meatus circumferentially, with a smooth, somewhat translucent lesion protruding from the vaginal introitus or even filling the vagina (Fig. 5). These cysts are usually asymptomatic and most drain spontaneously. Occasionally, surgical drainage is warranted.

Imperforate hymen can present with hydrocolpos in newborns due to the maternal estrogen stimulation of the uterus and cervical glands. On examination, a bulging, shiny, white or gray protuberance is noted over the vaginal introitus, but the urethral meatus can be noted anterior to the mass and is uninvolved

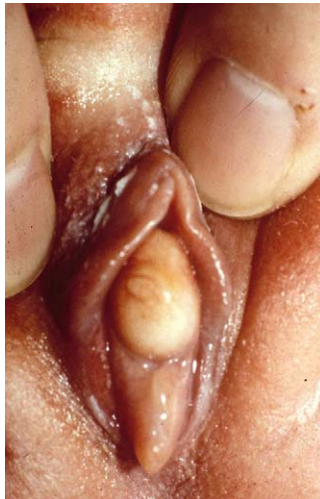

Fig. 5. Gartner's duct cyst.

(Fig. 6). Occasionally, the distended vagina can result in a palpable abdominal mass (from a distended bladder or uterus), urinary retention, or upper urinary tract obstruction. When this condition is not recognized until early adolescence, it may be discovered on evaluation for primary amenorrhea, usually accompanied by cyclic abdominal pain or a bulging, bluish introital mass.

Urethral prolapse is circumferential eversion of the urethral mucosa through the meatus. It is seen primarily in young black girls and tends to present with blood spotting in the underwear, dysuria, or itching. It can be distinguished from the other urethral anomalies seen in girls (prolapsed ureterocele and sarcoma botryoides) due to its circumferential nature. Treatment options vary, but simple options such as observation, topical antibiotic or estrogen creams, and sitz baths are usually successful. Surgical excision of the prolapsing mucosa is usually reserved for recurrent, symptomatic prolapse.

Prolapsed ureterocele is usually associated with ureteral duplication anomalies. A ureterocele is a cystic dilation of the distal ureter within the bladder, most often associated with a dilated, poorly functioning upper segment of a completely duplicated renal collecting system. It is usually seen in infancy and is more common in white girls. Early in the course, inspection of the urethral meatus should be possible and confirms that it is intact circumferentially. With prolonged prolapse, however, the mucosa of the ureterocele may progress from a smooth, glistening, pink surface to an engorged, congested, darker appearance, which can limit inspection of the introitus altogether (Fig. 7). Bladder outlet obstruction and significant upper tract abnormalities can coexist, so urgent referral and renal-

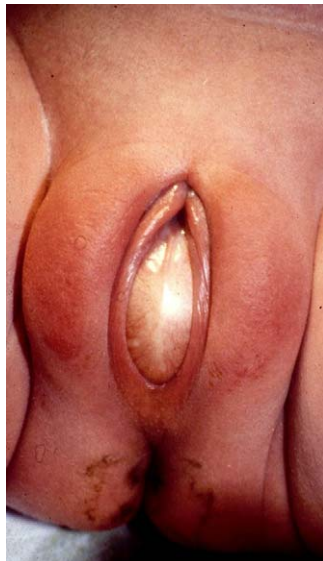

Fig. 6. Bulging imperforate hymen.

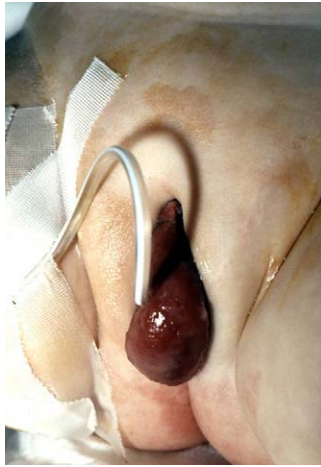

Fig. 7. Prolapsed ureterocele (urethral catheter in place).

bladder ultrasonography are indicated. Ultimately, these patients require a VCUG, nuclear renal scan, and definitive surgical intervention.

Sarcoma botryoides (rhabdomyosarcoma of the vagina) may present as an interlabial mass, classically described as a “cluster of grapes” extruding from the vaginal introitus. The mass is usually distinct from the urethral meatus. Renal-bladder sonography is always appropriate when this diagnosis is considered, as is urgent urologic referral.

Abdominal masses

Most neonatal abdominal masses arise from the retroperitoneum in general; many from the kidney itself. As with other neonatal conditions previously discussed, abdominal masses are now more frequently identified prenatally on ultrasound. Most masses have already been characterized as cystic, solid, or hydronephrotic and usually warrant urgent evaluation by a urologist, although few require emergent surgery.

Hydronephrosis remains the most common cause of an abdominal mass in a neonate. Renal sonography is important to evaluate the renal parenchyma and for the presence of ureteral dilation because hydronephrosis with a nonvisualized or normal-caliber ureter usually represents a ureteropelvic junction obstruction. A VCUG should also be obtained, and often a nuclear medicine renal scan is indicated, especially if ipsilateral reflux is absent. If reflux is not present and the renal scan reveals no function ipsilaterally, then multicystic dysplastic kidney (MCDK) becomes the likely diagnosis. It should be mentioned during the dis-

discussion of hydronephrosis that hydronephrosis associated with obstruction, along with signs or symptoms of pyelonephritis, represents a true urologic emergency requiring immediate decompression of the obstructed upper tract in addition to broad-spectrum intravenous antibiotics. This decompression of the obstructed kidney is usually accomplished with a percutaneous nephrostomy tube or ureteral stent placement. Patients who have obstructed pyelonephritis may rapidly decompensate if the obstruction is not promptly relieved.

MCDK is the second most common cause of a neonatal abdominal mass. No intervention is generally recommended for MCDK unless the size of the kidney, which can be very large, leads to respiratory compromise or feeding problems due to compression of the gastrointestinal tract. There is a very small risk of hypertension and malignancy associated with the abnormal kidney.

Inherited renal abnormalities can present in infancy and childhood in the form of autosomal recessive polycystic kidney disease (ARPKD) and autosomal dominant polycystic kidney disease (ADPKD), formerly known as “adult” polycystic kidney disease. Because these diseases are generally bilateral, they can usually be differentiated from hydronephrosis and MCDK: the latter conditions are usually unilateral. Children who have ARPKD have massively enlarged kidneys that are homogeneously hyperechoic on ultrasound, with no dominant cysts identified. They may present with Potter fascies, oligohydramnios, pulmonary hypoplasia, and hepatic fibrosis. Long-term prognosis is generally poor, with those surviving the neonatal period often requiring dialysis or renal transplantation.

ADPKD may present in infancy, diagnosed by prenatal ultrasound, or later in childhood or adulthood when it is associated with hypertension, renal insufficiency, proteinuria, or hematuria. Infants who have ADPKD may have massive renomegaly. In contrast to ARPKD, the cysts tend to grow larger with time. The prognosis is much better for these patients, although many ultimately develop renal failure and require dialysis or transplantation.

Multilocular cystic nephroma is an uncommon cystic renal tumor that has a bimodal presentation, seen primarily in young boys (6 months to 4 years) and middle-aged women. It is a benign tumor that usually presents in children as a palpable mass. Ultrasound and CT reveal a tumor composed of multiple cysts of various sizes with thin walls. If solid areas or nodularity of cyst walls is seen, then other diagnoses should be considered, such as a cystic Wilms’ tumor. Treatment involves nephrectomy and is curative.

Solid renal masses seen in infants and children include congenital mesoblastic nephroma, Wilms’ tumor, renal vein thrombosis, and renal cell carcinoma. Neuroblastoma and adrenal hemorrhage are not discussed because they are now generally managed by pediatric general surgeons.

Congenital mesoblastic nephroma is the most common cause of a solid mass in an infant younger than 6 months, with most masses presenting in the first month of life. It usually appears as a solid mass on sonography and a low attenuation lesion on CT scan. Although this tumor rarely metastasizes, it can be locally invasive and thus surgical resection is indicated.

Wilms' tumor is rarely the cause of a renal mass in a newborn but is the most common malignant renal tumor of childhood. The most common age for presentation is 3 to 4 years, although bilateral disease may present earlier. The most common presenting symptom remains an abdominal mass, perhaps associated with hypertension, hematuria, and flank or abdominal pain. Sonography and CT scan typically reveal a well-defined solid mass, arising from and compressing adjacent parenchyma. It typically does not invade local structures, unlike neuroblastoma, but renal vein and inferior vena caval tumor thrombi can be present. Combined chemotherapy and surgery results in a very favorable prognosis for most of these children.

Renal vein thrombosis may also present as an abdominal mass in a neonate. The classic presentation is that of an ill neonate who has hypertension, proteinuria, an enlarged kidney, and hematuria. Risk factors include severe dehydration, hypotension, sepsis, asphyxia, prematurity, and maternal diabetes. Renal ultrasound reveals an enlarged kidney with echogenic streaks radiating peripherally within the parenchyma, with poor corticomedullary differentiation. Occasionally, a thrombus can be identified in the main renal vein or one of its tributaries. CT scan reveals an enlarged, edematous kidney with poor perfusion and function. Treatment of unilateral thrombosis is supportive, with hydration and close monitoring. Bilateral renal vein thrombosis requires more aggressive treatment with anticoagulation or systemic thrombolytics.

Although renal cell carcinoma is primarily a disease of adulthood, it can be seen in childhood, with a peak incidence in childhood at age 11 years. It typically presents with pain, hematuria, or a flank mass. Ultrasound reveals a solid or partially solid mass, and CT scan reveals an enhancing tumor within the parenchyma, similar to Wilms' tumor. Management involves partial or radical nephrectomy, depending on tumor location and size. Prognosis depends on grade, stage, and pathology of the tumor.

Summary

The objective of this article is to provide primary care clinicians with a review of the most commonly seen genitourinary processes that require emergent or urgent evaluation by a urologist familiar and comfortable with children.

References

- [1] Dresner ML. Torsed appendage. Diagnosis and management: blue dot sign. *Urology* 1973;1(1): 63–6.
- [2] Baker LA, Sigman D, Mathews RI, et al. An analysis of clinical outcomes using color Doppler testicular ultrasound for testicular torsion. *Pediatrics* 2000;105(3):604–7.
- [3] Kravchick S, Cytron S, Leibovici O, et al. Color Doppler sonography: its real role in the evaluation of children with highly suspected testicular torsion. *Eur Radiol* 2001;11(6):1000–5.

- [4] Schwartz RH, Rushton HG. Acute balanoposthitis in young boys. *Pediatr Infect Dis J* 1996; 15(2):176–7.
- [5] Morey AF, Bruce JE, McAninch JW. Efficacy of radiographic imaging in pediatric blunt renal trauma. *J Urol* 1996;156(6):2014–8.
- [6] Gatti JM, Perez-Brayfield M, Kirsch AJ, et al. Acute urinary retention in children. *J Urol* 2001; 165(3):918–21.