

VIDEOS IN CLINICAL MEDICINE

Male Urethral Catheterization

Todd W. Thomsen, M.D., and Gary S. Setnik, M.D.

INDICATIONS

Urethral catheterization may be performed for diagnostic or therapeutic purposes. Therapeutically, catheters may be placed to decompress the bladder in patients with acute or chronic urinary retention as a result of conditions such as infravesicular obstruction of the urinary tract or neurogenic bladder. Catheterization and subsequent irrigation may be required in patients with gross hematuria to remove blood and clots from the urinary bladder. Diagnostically, urethral catheterization may be performed to obtain an uncontaminated sample of urine for microbiologic testing, to measure urinary output in critically ill patients or during surgical procedures, or to measure the residual urine volume after voiding if noninvasive methods (such as ultrasonography) are not available.¹

Catheters should not be used for the routine management of urinary incontinence. If feasible, less invasive measures (such as incontinence pads, intermittent catheterization, or penile-sheath catheters) should be used in order to avoid the complications of indwelling catheterization. In addition, surgery to correct incontinence or the use of antimuscarinic agents may be beneficial in selected patients.

CONTRAINDICATIONS

The only absolute contraindication to urethral catheterization is urethral injury, either confirmed or suspected. Urethral injury is usually encountered in patients who have had substantial trauma to the pelvis or patients who have a pelvic fracture. Physical findings associated with urethral injury include blood at the urethral meatus and gross hematuria (found in more than 90 percent of cases of urethral disruption), perineal hematoma, and a “high-riding” prostate gland. A high-riding prostate gland may be obscured by the presence of a large pelvic hematoma or may be missed if the patient is reluctant to have a thorough examination owing to tenderness in the area. The use of retrograde urethrography is mandatory before catheterization if a urethral injury is suspected.²

Relative contraindications to urethral catheterization include urethral stricture, recent urethral or bladder surgery, and a combative or uncooperative patient.

PREPARATION

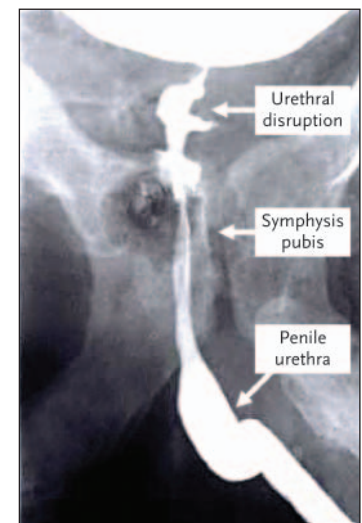
The equipment required for urethral catheterization is often available in a prepackaged catheterization tray. A typical tray includes sterile gloves, antiseptic solution, sterile drapes, a Foley catheter, sterile lubricant, forceps and cotton balls, sterile water for balloon inflation, and tubing and a collection bag. Additional required equipment that is often not in the prepackaged tray includes viscous lidocaine, tape or another device to secure the catheter to the patient, and occasionally, antiseptic solution.

Numerous sizes and types of urethral catheters are available. The Foley catheter — a double-lumen, straight-tip catheter — is used most frequently. The coude cath-

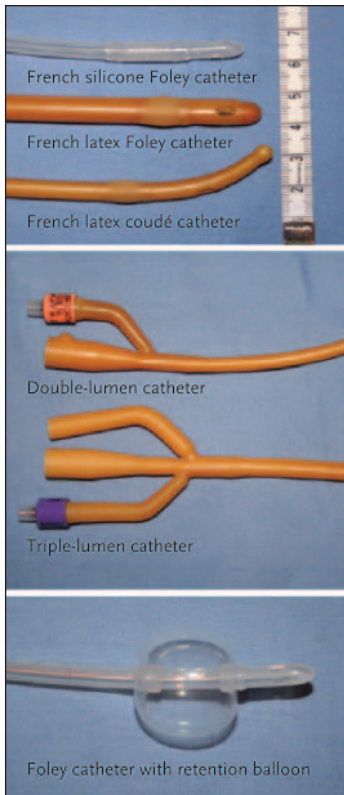
From the Department of Emergency Medicine, Mount Auburn Hospital, Cambridge, Mass.; and the Division of Emergency Medicine, Harvard Medical School, Boston. Address reprint requests to Dr. Thomsen at the Department of Emergency Medicine, Mount Auburn Hospital, 330 Mount Auburn St., Cambridge, MA 02238, or at tthomsen@mah.harvard.edu.

N Engl J Med 2006;354:e22.

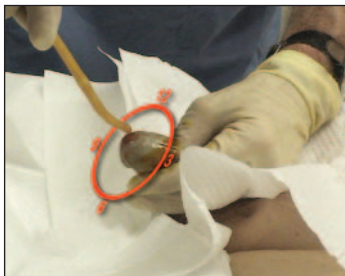Copyright © 2006 Massachusetts Medical Society.



Retrograde urethrogram showing extravasation of urine



Various types of urethral catheters



eter has a semirigid, curved tip that facilitates placement in patients with prostatic enlargement. Triple-lumen (“three-way”) catheters have an additional port for bladder irrigation. Most catheters have a retention balloon on the distal end that, when filled with water, holds the catheter in place inside the bladder.

For most men, a 16-French or 18-French catheter is the appropriate size. Smaller catheters (12-to-14 French) may be required in patients with urethral stricture, whereas larger ones (20-to-24 French) may be needed in patients with prostatic enlargement to avoid kinking of the catheter as it traverses the prostatic urethra.³ Larger catheters should also be used in patients with gross hematuria to prevent obstruction of the lumen by blood clots and subsequent urinary retention.

Many catheters are made of latex; however, silicone-based versions are available for patients with latex sensitivity or allergy. Catheters coated with silver alloy resist bacterial growth and may be used in patients at high risk for infection.⁴

CATHETERIZATION

Inspect all equipment, and arrange it within reach on a bedside table. Temporarily inflate the retention balloon to check the integrity and function of the valve, and attach the catheter to the tubing on the collection unit.

Place the patient on a stretcher in the supine position, and fully retract the foreskin if he is uncircumcised. Inject 10 to 15 ml of viscous lidocaine into the urethral meatus (with the use of a needle-less syringe), both to anesthetize the mucosa and to distend the urethra, which will facilitate catheterization. Pinch the tip of the penis for several minutes after the lidocaine injection to retain the jelly in the urethra.

Urethral catheterization is performed under sterile conditions, and sterile gloves should be worn throughout the remainder of the procedure. After draping the pubic region and proximal thighs, grasp the penile shaft with your nondominant hand, holding the penis taut and perpendicular to the plane of the patient’s body. This hand is now considered nonsterile and should not release the penis or touch any sterile equipment. Cleanse the glans penis in a circular motion, using cotton balls soaked in antiseptic.

Lubricate the tip of the catheter with sterile jelly or viscous lidocaine before inserting it. If a coudé catheter is used, point the tip of the catheter upward, in the 12 o’clock position, to facilitate passage around the median lobe of the prostate gland. Gently introduce the catheter into the meatus and slowly advance it proximally through the urethra. If substantial resistance is encountered at this stage, do not forcefully advance the catheter, since this approach is likely to be unsuccessful and may result in urethral trauma. Some resistance may be encountered at 16 to 20 cm, which is in the region of the external sphincter. Instructing the patient to relax the sphincter and breathe deeply may facilitate passage of the catheter. Advance the catheter to the level of the balloon-inflation port.

The return of urine into the collection tubing signifies that the catheter is in the proper position. There may be a lack of flow if the catheter is obstructed by lubricating jelly or the bladder is empty. Flush the catheter with saline; the free return of urine or saline confirms that the catheter is properly positioned.

Next, inflate the balloon with 10 ml of water. (Various types of catheters may have various balloon capacities; check the inflation port on the distal end of the catheter for the proper volume.) Only water should be used, since air may leak from the balloon and saline may crystallize and cause malfunction of the valve or obstruction of the lumen, preventing proper deflation. It is of utmost importance to fill the balloon while the catheter is fully inserted to avoid intraurethral inflation.

Finally, gently pull the catheter back to seat the balloon against the bladder wall. To prevent paraphimosis, make sure the foreskin is reduced to its anatomical

position in uncircumcised patients. Affix the catheter to the patient's thigh or anterior abdominal wall with tape or another fixation device, and hang the collection bag in a dependent position.

TROUBLESHOOTING

In patients with prostatic enlargement, resistance to advancement of the catheter may occur at 16 to 20 cm. Successful catheterization in such patients may be achieved with the use of a coudé catheter. If a coudé catheter is not available, a large (20-to-24-French) Foley catheter may be used. The use of small catheters should be avoided, since they tend to kink when resistance is encountered.

A urologic consultation should be obtained if the urethra cannot be entered owing to severe phimosis or meatal stenosis or if there is substantial resistance during passage of the catheter.¹ If the catheter kinks in the urethra and a bloody discharge is noted, urethral perforation may have occurred. The catheter should be withdrawn, no further attempts at passage should be made, and a urologic consultation should be obtained.

COMPLICATIONS

Urinary tract infections are common after urethral catheterizations, occurring in 3 to 10 percent of patients per day of catheterization. Although many infections are limited to asymptomatic bacteriuria, in some instances, pyelonephritis, bacteremia, and urosepsis develop. The potential for serious illness or death is real, since nosocomial urinary tract infections have been shown to extend hospital stays by three days and to triple the mortality rate in catheterized patients. Patients at increased risk for catheter-related infections include the elderly, persons with diabetes, and those with underlying renal insufficiency or advanced, life-threatening illnesses.⁴

The most effective way to prevent urinary tract infections is to avoid catheterization whenever possible. If the procedure must be performed, preventive measures include the use of a strict aseptic insertion technique, the diligent maintenance of a closed collecting system, and the reduction of the duration of catheterization. The routine use of prophylactic antibiotics is not beneficial and encourages the proliferation of resistant species. However, antibiotic treatment should be considered for patients at high risk for infection and for those undergoing certain invasive procedures, such as transurethral resection of the prostate and renal transplantation.⁴

Other complications of urethral catheterization include paraphimosis and trauma to the urethra and bladder. Occasionally, it may not be possible to deflate the retention balloon, owing to obstruction of the secondary lumen or malfunction of the valve. In the latter case, cutting off the side arm and removing the valve may solve the problem. If this fails, a urologic consultation is indicated, since the balloon may need to be punctured with the use of a suprapubic approach and ultrasonographic guidance.⁵

REFERENCES

1. Schneider RE. Urologic procedures. In: Roberts JR, Hedges JR, eds. *Clinical procedures in emergency medicine*. 4th ed. Philadelphia: W.B. Saunders, 2004:1086-98.
2. Koraitim MM. Pelvic fracture urethral injuries: the unresolved controversy. *J Urol* 1999;161:1433-41.
3. Cancio LC, Sabanegh ES Jr, Thompson IM. Managing the Foley catheter. *Am Fam Physician* 1993;48:829-36.
4. Saint S, Lipsky BA. Preventing catheter-related bacteriuria: should we? Can we? How? *Arch Intern Med* 1999;159:800-8.
5. Daneshmand S, Youssefzadeh D, Skinner EC. Review of techniques to remove a Foley catheter when the balloon does not deflate. *Urology* 2002;59:127-9.

Copyright © 2006 Massachusetts Medical Society.